

## **A Case of Tuberculosis of Maxillary Sinus**

**Ashfak R. Kakeri<sup>\*</sup>, Anees Fathima H. Patel, B.N.Walikar,  
Milind V Watwe and Satish M Rashinkar**

<sup>1</sup>*Department of E.N.T, Al Ameen Medical College Hospital, Bijapur-586108,  
Karnataka, India*

**Abstract:** Tuberculosis of the maxillary sinus is rare. Although involvement of long bones and vertebral column is common, its quite uncommon in flat bones. We describe here a case of tuberculosis of the maxillary sinus, and discuss the clinical features and its management.

### **Introduction**

Tuberculosis, one of the oldest disease in man, is even today a leading cause of human suffering and loss of life. *Mycobacterium tuberculosis*(*humanis/bovis*) most frequently reaches the lungs and rarely involves paranasal sinuses, nasopharynx, nose and facial bones, through blood stream or lymphatics[1]. Gleitsmann reviewed the literature on Tuberculosis of maxillary antrum[2]. Its sometimes confused with granulomatous or neoplastic processes for which reason sometimes diagnostic suspicion is important. Although the incidence of mycobacterial diseases especially the extrapulmonary type is on the rise in many regions of the world, it still remains an underdiagnosed entity. Its because of occasional and uncommon clinical presentation with the involvement of atypical sites[1]. There are mainly three types of pathologies seen in sinonasal tuberculosis. In the first type, infection is confined to mucosa only, leading to polypi filling the antrum and minimal pus discharge. Second type has bony involvement and fistula formation, discharge is abundant with teaming bacilli. Third type is associated with hyperplastic changes and formation of tuberculoma[6].

### **Case History**

A 15 year old boy came to the OPD with a 2 month history of gradually increasing swelling in front of left cheek, in the infraorbital region. It was soft to firm in consistency, free from the overlying skin. Nasal examination revealed purulent discharge from left middle meatus. He was on oral antibiotics from last one month, but the swelling persisted. Haemogram report revealed TLC-6800, P-41%, L-49%, M-5%, E-5%, ESR – 40 mm after one hour by Westergreen method, X-ray of the paranasal sinus revealed haziness in the left maxillary sinus. CT-Scan of the region-fig.1 reveals soft tissues swelling over the left maxilla with osteomyelitic changes in the anterior wall of maxilla. Serological IgM test for tuberculosis was positive.

A sublabial approach was taken under general anaesthesia, brownish soft tissue mass with granulations was removed, through the diseased anterior wall of maxilla, antrum was reached and the granulation tissue removed. The specimen was sent for HPR,

which revealed necrotizing granulomas with caseation, epitheloid cells and lymphocytes. AFB was negative. Special stains for fungi were negative. Post operative recovery was uneventful. Patient was started on Antituberculosis treatment. Patient has been observed after the surgery for one year without any residual disease after completing the treatment..

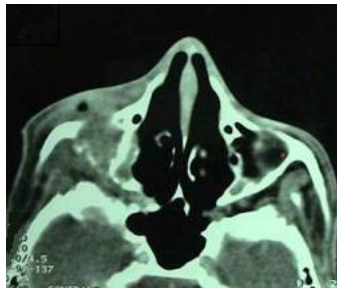


Figure 1: Showing axial CT Scan of PNS

### , Discussion

Most cases of tubercular involvement of the maxillary sinus are secondary to pulmonary tuberculosis[1]. Gleitsmann in 1907 reported that a search of literature revealed 20 cases of Maxillary Sinus Tuberculosis, other sinuses were infected less frequently[2]. The facial bones are unusual sites for tuberculosis and very few cases of maxillary sinus tuberculosis have been reported [3,4]. These cases can present with complications like, Shukla et al reported a case of tuberculosis maxillary sinus that featured an abscess in the brain[5], Jain et al reported that orbital involvement can manifest with deterioration of vision[6]. Rarely it has been associated with carcinoma[7]. Clinically the tuberculosis of maxillary sinus is characterized by lack of early symptoms and appearance of fluctuant swelling i.e. Pott's Puffy tumour as usually the first symptom , as in our case[6]. With positive mantoux test and enlarged hilar glands which are however common findings even in healthy individuals in our subcontinent, the probable diagnosis is only possible after surgical exploration of growth and confirmation of its histopathological examination[6]. Serological test of demonstrating IgM specific antibodies for tuberculosis have also been very useful. CT scan may demonstrate lytic or sclerotic changes. In this era where very effective ATT is available, this case of maxillary sinus tuberculosis serves as a reminder that the disease is still active in third world countries and that every ENT surgeon should always consider it under differential diagnosis of patients with swelling in relation to maxilla.

### References

1. Meher Ravi, Garg Ashu, Tubercular Osteomyelitis of Maxilla – Calicut Medical Journal. 2005; 3(3): e4
2. Gleitsmann JW, Tuberculosis of Accessory Sinuses of the Nose. Laryngoscope- 1907;17:445

3. Shukla GK, Dayal D, Chabra DK. Tuberculosis of maxillary sinus. *J Laryngology Otolology*. 1972;86:747-54.
4. Page JR, Jash DK. Tuberculosis of the nose and paranasal sinuses . *J Laryngology Otolology*. 1974;88:579-83.
5. Mahendra S., Bais AS, Sohail MA, Maheshwari HB, Granulomatous osteomyelitis of the maxillary sinus. *Otolaryngol*. 1979;8:255-8.
6. Jain MR, Chundawat HS, Batra V. Tuberculosis of the maxillary antrum and of the orbit. *Indian J Ophthalmol*. 1979;27:18-20.
7. Sharma M.C. Tuberculosis of the maxillary sinus manifesting as a facial abscess- *Ear, Nose and Throat Journal*. 2002; 1-2
8. Bhat Nalini, Subramaniam Vinayak. Tuberculosis in ear, nose and throat practice: its presentation and diagnosis. 2006; 27:39-45
9. Rosenquist JB, Beskow R. Tuberculosis of the maxilla: Report of case. *J Oral Surgery*. 1977; 35:309-10.

*\*All correspondences to: Dr. Ashfak Ahmed R. Kakeri, Associate Professor, Dept of ENT, Al-Ameen Medical College, Bijapur- 586108, Karnataka, India*