

## Morphometric analysis of hard palate in eastern Indian population

Iman Sinha<sup>1\*</sup>, Ratnadeep Poddar<sup>2</sup> and Ratul Basu<sup>3</sup>

<sup>1</sup>Department of Anatomy, Institute of Post Graduate Medical Education and Research, 244, AJC Bose Road, Kolkata-700020, West Bengal, India, <sup>2</sup>Department of Anatomy, Rampurhat Government Medical College and Hospital, Rampurhat, Birbhum-731224, West Bengal, India and <sup>3</sup>Department of Anaesthesiology, ICARE Institute of Medical Sciences and Research & Dr. Bidhan Chandra Roy Hospital, Haldia-721645, West Bengal, India

Received: 20<sup>th</sup> August 2020; Accepted: 12<sup>th</sup> October 2020; Published: 01<sup>st</sup> January 2021

**Abstract:** *Background:* Knowledge of morphologic variation of hard palate is very important to dental surgeons as well as to anthropologists. *Aim:* Our study aimed to measure various parameters of hard palate and details of location of greater palatine foramen with reference to some anatomical landmarks in human skull in eastern Indian population. *Materials and Methods:* 120 dry human skull bones have been studied in an institution in eastern India. Length, breadth and height of hard palate were measured. Location and dimensions of greater palatine foramen with respect to incisive foramen, midline maxillary suture, posterior border of the hard palate, base of pterygoidhammulus and posterior nasal spine were measured. Direction of greater palatine canal was also noted. *Results:* The mean palatal height, breadth and length were  $12.31 \pm 3.25$  mm,  $33.86 \pm 2.77$  mm and  $42.68 \pm 1.99$  mm in male and  $13.75 \pm 2.86$  mm,  $32.94 \pm 2.37$  mm and  $39.01 \pm 0.74$  mm in female skulls respectively. The position of greater palatine foramen was at level of 3<sup>rd</sup> molar teeth in most of the skull (85.2% in male skulls and 86.67% in female skulls).

**Keywords:** Greater Palatine Foramen, Hard Palate, Incisive Foramen.

### Introduction

The human race has an evolutionary advantage of reasoning over the other vertebrates for ages. Expressing oneself linguistically and unfolding the deep emotions are the unique characteristics of the *Homo sapiens (sapiens)*. Eventually, the articulation of speech is an important maneuver, which had been adapted by the human beings. These complex series of events occurring relentlessly for producing meaningful expressions, need a concrete anatomical basis in form of some bony structures, muscles and other soft tissues, which are in turn co-ordinated smoothly and rather quickly by the integrated nervous system. Hence, the hard palate has an important role in speech articulation and its shape acts as one of the major factors for modulation of speech and accent. Following death with serious damages, some bony and dental structures of the palate are often preserved. Using morphometric observation of the hard palate, sex determination has been affirmed by Burris and Harris [1]. Maxillary nerve blocks are commonly performed by dental

surgeons and anaesthesiologists. Localization of the foramen is crucial in establishing local anaesthesia by maxillary nerve block [2]. This approach has a high success rate with minimal risk [3].

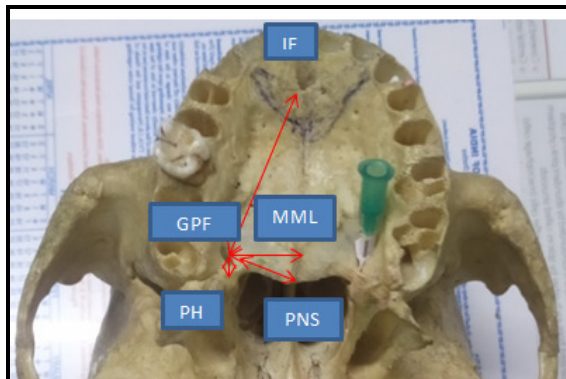
A further advantage of this approach is the fact that the needle traverses the shortest route to block the maxillary nerve [4]. Blocking sensation of the maxillary nerve in the pterygo palatine fossa (PPF) achieves anaesthesia of the maxillary teeth, the maxillary palate and gingival tissues, as well as the skin of the mid face, nasal cavity, and sinus. Such a maxillary block would be necessary before various surgical procedures in this region, in patients with maxillary trauma, and for the diagnosis and treatment of chronic oral and maxillofacial pain syndromes. Furthermore, as simple infiltration into the buccal sulcus, adjacent to the tooth to be worked on, may be contraindicated in patients with an infection in the region, dentists may also need to resort to maxillary nerve blocks [5].

**Material and Methods**

This is an observational study. 120 dry human skull bones of either sex (77 male and 43 female) were studied in an institution in eastern India. Skull bones without any anomaly, pathology and fractures were chosen only. By the time there is obliteration of the sphenoccipital suture, the skull ages above 25 year old [5].

Skull bones where sphenoccipital suture was obliterated, were included in the study. Length, breadth and height of hard palate were measured. Location and dimensions of greater palatine foramen with respect to incisive foramen, midline maxillary suture, posterior border of the hard palate, base of pterygoidhammulus and posterior nasal spine were measured. Direction of greater palatine canal was also noted. All the measurements were taken bilaterally directly thrice from those skulls. Mean of the three readings are taken into consideration. Tools used were ruler, protractor, slide callipers with 0.02mm precision, marker pen, 25 G needle and rubber stop. The statistical analysis was done using SPSS software version 2021. Measures of central tendency were calculated and statistical significance was ascertained using students’ t test.

**Fig-1:** Showing glimpse of the measured parameters



Length of the palate was regarded as the distance between the anterior most point of the incisive suture, located in between the sockets of medial

maxillary incisor teeth of either side, to posterior nasal spine. Breadth was measured as the distance between the sockets of upper second molar teeth of either side. Height of palate was regarded as the distance of highest arching point of the palate from a horizontal plane connecting the two maxillary second molars of either side.

The following indices were calculated according to the method followed by Hassanali and Mwaniki [6]: the palatine index (PI) and the palatine height index (PHI). The PI is the ratio of the palatine breadth to the palatine length expressed as a percentage. The values of the PI indicate the width of the palate. When the PI range was 79% or less, the hard palate was narrow (lepto-staphyline); when the PI range was 80-84.9%, the hard palate was intermediate (meso-staphyline); and when the PI range was 85% or more, the hard palate was wide (brachy-staphyline). The PHI is the ratio of palatine height to the palatine breadth expressed as a percentage. It indicates the characteristic arching of the palates. When the PHI was 27.9% or less, the hard palate was low (chame-staphyline); when it was 28-39.9%, the hard palate was intermediate(ortho-staphyline); and when it was 40% or more, the hard palate was deep (hypsi-staphyline).

**Results**

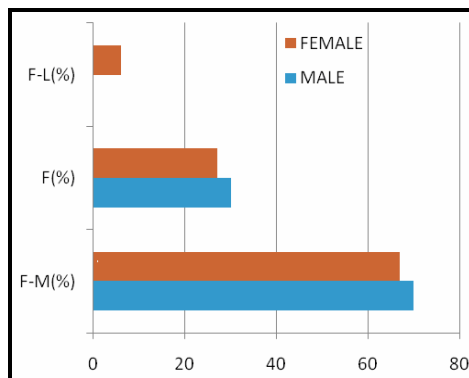
The mean palatal height, breadth and length (as measured in the index study) were 12.31 ± 3.25 mm, 33.86 ± 2.77 mm and 42.68 ± 1.99 mm in male and 13.75 ± 2.86 mm, 32.94 ± 2.37 mm and 39.01 ± 0.74 mm in female skulls respectively. There has been statistically significant difference among the palatal lengths in skulls of male and female specimens, as depicted in Table 1, while the breadth and height did not vary significantly between either of genders.

<b>Table-1: Anthropometric data of either genders with respect to height, breadth and length of hard palate</b>				
<b>Parameters</b>	<b>Male (in mm)</b>	<b>Female (in mm)</b>	<b>p value</b>	<b>Statistically Significant</b>
Palatal Height	12.31 ± 3.25	13.75 ± 2.86	0.161	X
Palatal Breadth	33.86 ± 2.77	32.94 ± 2.37	0.287	X
Palatal Length	42.68 ± 1.99	39.01 ± 0.74	<0.001	√

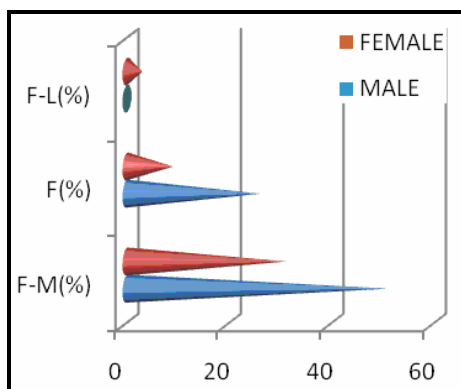
The position of greater palatine foramen was at level of 3<sup>rd</sup> molar teeth in most of the skull (85.2% in male skulls and 86.67% in female skulls). Only a few were seen at junction between 2<sup>nd</sup> and 3<sup>rd</sup> molar (13.3% in female skulls and 3.7% in male skulls). None of the female skulls showed position of the greater palatine foramen beyond the 3<sup>rd</sup> molar teeth while a very few of male skulls (7.4%) revealed the greater palatine foramen just posterior to the level of 3<sup>rd</sup> molar teeth.

70 %of male specimen and 67 % of female specimen revealed the direction of greater palatine canal (GPC) to be forward and medially on right side, while the same direction was seen in 67 % of male specimen and 73 % female specimen on left side respectively. The female skulls showed a small percentage GPC to be directed forward and laterally (6% on either side). These comparative data between either sides and genders are shown in figures 2 & 3.

**Fig-2:** Direction of right GPC among Male and Female skulls: F-M = Forward & medially, F = Forwards, F-L = Forwards & Laterally



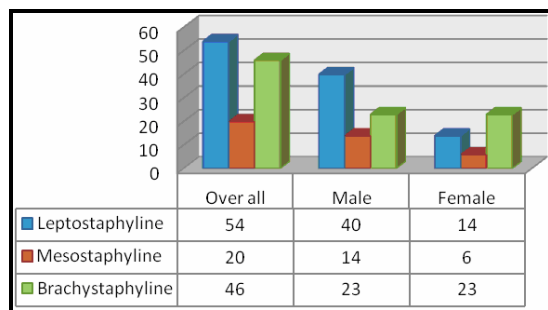
**Fig-3:** Direction of left GPC among Male and Female skulls: F-M = Forward & medially, F = Forwards, F-L = Forwards & Laterally



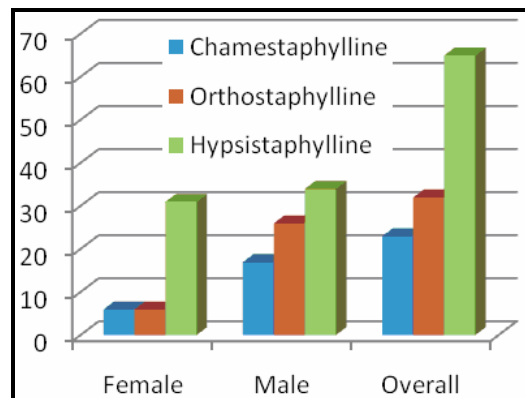
Based on the Palatal Index (PI), the skulls can be divided into three categories, namely Leptostaphyline, Mesostaphyline & Brachystaphyline, while on the basis of their Palatal Height Index (PHI) they can be categorised into another three varieties, viz. Chamestaphyline, Orthostaphyline & Hypsistaphyline.

The index study showed overall 45% of the skulls were Leptostaphyline and 55% were Hypsistaphyline. However, when the gender variation was considered, most of the male skulls were Leptostaphyline (52%) and most of female skulls were Brachystaphyline (53%), on basis of PI. On the other hand, based on PHI, in both the genders, most of the skulls were seen to be Hypsistaphyline (45% male and 74% female). These results are shown in figures 4 & 5.

**Fig-4:** Bar diagram showing types of skulls, on basis of palatal index (PI)



**Fig-5:** Showing types of skulls, on basis of palatal height index (PHI)



The other various parameters that were measured in the present study are summarized in table 2. It is evident that most of the parameters did not show any statistically

significant gender variability except for the distance between Incisive foramen (IF) and the anterior margin of greater palatine foramen (GPF)

on either side. The p value for right and left sides being 0.0049 and 0.032 respectively, for the mentioned parameters.

**Table-2: Comparison between the male and female skulls on basis of study parameters**

Parameter	Right Side (in mm : mean ± SD)			Left Side (in mm : mean ± SD)		
	Male	Female	p value	Male	Female	p value
IF-GPF	37.42 ± 2.52	35.23 ± 1.77	0.0049	37.14 ± 2.46	35.58 ± 1.54	<b>0.032</b>
MML-GPF	13.44 ± 1.43	13.16 ± 1.31	0.54	13.34 ± 1.53	13.3 ± 1.06	0.93
PNS-GPF	15.37 ± 1.35	15.53 ± 1.13	0.69	15.37 ± 1.53	15 ± 1.34	0.43
PH-GPF	9.04 ± 1.03	8.36 ± 1.42	0.08	9.06 ± 1.69	8.9 ± 1.21	0.76

**IF** = Incisive Foramen; **MML** = Middle Maxillary Line (Suture); **PNS** = Posterior nasal spine; **PH** = Base of pterygoidhamulus; **GPF** = Greater palatine foramen; **GPC** = Greater palatine canal;

### Discussion

The mean palatal height, breadth and length were 12.31 ± 3.25 mm, 33.86 ± 2.77 mm and 42.68 ± 1.99 mm in male and 13.75 ± 2.86 mm, 32.94 ± 2.37 mm and 39.01 ± 0.74 mm in female skulls respectively. There has been statistically significant difference among the palatal lengths in skulls of male and female specimens. Mustafa et al. [7] found that the mean palatal length in male and female skulls was, 43.91 ± 2.65 mm & 39.53 ± 2.73 mm respectively, and the mean palatal breadth in male and female skulls was 45.05 ± 2.47mm & 40.23 ± 2.01mm respectively in Jordanian population.

Gangrade et al. [8] found mean palatal length in male and female skulls 54.59 and 52.44mm, respectively. The palatal breadth in male and female skulls was 38.49 and 35.89 mm, respectively; statistical analysis showed a significantly higher value of palatal length and breadth in male skulls compared with female skulls. Shalaby et al.[9] found that the mean palatal length was 52.77 ± 5.160 mm in male skulls and 49.66 ± 2.78 mm in female skulls, and the mean palatal breadth was 39.23 ± 3.02 and 37.7 ± 2.28 mm in male and female skulls, respectively. The average values of maximum palatal length and breadth in male skulls was significantly higher than those in female skulls (P < 0.001).

Anil Kumar et al [10] found statistically significant difference in the morphology and dimensions between female and male palatal

length and breadth. Male seems to have greater palatal length (52.5 ± 0.37) and breadth (36.51 ± 0.27) compared to female palatal length (48.1 ± 0.36) and breadth (32.33 ± 0.20). On the other hand, height of the palate in male is (16.81 ± 2.7) compared to the female (14.2 ± 0.20), with no statistically significant difference between both sexes in Indian population.

In our study, we found that the position of greater palatine foramen was at level of 3<sup>rd</sup> molar teeth in most of the skull (85.2% in male skulls and 86.67% in female skulls). Sujatha et al. [11] observed this location in 85.95% of Indian skulls, which is at per with our study whereas Wang et al. [12] reported the same location in only 33.5% of Chinese skulls. Similar results were obtained by Hassanali and Mwaniki (76%), D'Souza et al (73.75%), Jotania et al (78.33%) and Erli Sarlita et al (58.7%) [6, 13-15].

70 % of male specimen and 67 % of female specimen revealed the direction of greater palatine canal (GPC) to be forward and medially on right side, while the same direction was seen in 67 % of male specimen and 73 % female specimen on left side respectively. Vinay KV et al [16] reported that GPF was directed anteromedial in 43.33% skulls. Abu Ubaida Siddiqui et al [17] described that in 69.4% skulls it was directed forward and medial. The study of Nidhi Sharma et al [18] also found to be correlated with the present study since most common

direction was anteromedial in 60.10% skulls. But Renu C reported the direction of GPF in North Indian skulls as vertically downwards, downwards and forwards in 93.5% and 6.5% cases respectively [19]. Study of Vaibhav P Anjankar et al [20] showed that in the majority, 74.42% skulls the GPF were directed anterolateral, 15.12% skulls as anterior, in 6.98% skulls anteromedial and in 3.48% skulls as vertical.

Based on the Palatal Index (PI) and Palatal Height Index (PHI), around 45% of the skulls were Leptostaphyline (narrow) and 55% were Hypsistaphyline (deep). However, when the gender variation was considered, most of the male skulls were Leptostaphyline (narrow) (52%) and most of female skulls were Brachystaphyline (wide) (53%), on basis of Palatal Index (PI). On the other hand, based on Palatal Height Index (PHI), in both the genders, most of the skulls were seen to be Hypsistaphyline (deep)(45% male and 74% female).

Shalabyet. al [9] found that 64% of Egyptian skulls had narrow palates (leptostaphyline). Hassanali and Mwaniki [6] also found 43% narrow palates, 33% wide palates and 24% intermediate palates. D'Souza *et al.* [13] in South Indian skulls, found that 37.5% of the palates were narrow, 40% were wide, and 22.5% were intermediate. In this study, low palates were more in male skulls than in female skulls and the difference was significant. In the total sample, 56% had intermediate arched palates

(orthostaphyline), 36% had low palates (chamestaphyline), and 8% had highly arched palates (hypsistaphyline). Findings of their study differ from our study in this regard. As our study was done in Eastern India and we procured our samples from this region, that could be very important reason for this difference.

In our present study, among the other parameters that we measured, statistically significant gender variability is found for the distance between Incisive foramen (IF) and the anterior margin of greater palatine foramen (GPF) on either side.

### Conclusion

Our present study will definitely enrich the morphometric database of palatal anatomy in Eastern Indian population. Till date very few palatal morphometric data are available regarding gender variation in Eastern Indian population. So, the data found in this study will certainly be helpful for the dental surgeons as well as for the anaesthesiologists for the purpose of local anaesthesia.

### Acknowledgement

The authors sincerely express their thanks and gratitude to the the-then Director of Institute of Post Graduate Medical Education & Research, Kolkata and the HOD, Department of Anatomy, Institute of Post Graduate Medical Education & Research, Kolkata for providing us necessary permissions to carry on the study.

**Financial Support and sponsorship:** Nil

**Conflicts of interest:** There are no conflicts of interest.

### References

- Burris BG, Harris EF. Identification of race and sex from palate dimensions. *J Forensic Sci* 1998; 43:959-963.
- Chrcanovic BR, Custódio AL. Anatomical variation in the position of the greater palatine foramen. *J Oral Sci* 2010; 52:109-113.
- Malamed SF. Handbook of local anesthesia. 5th ed. St. Louis: *Elsevier Mosby*; 2004.
- Methathrathip D, Apinhasmit W, Chompoopong S, Lertsirithong A, Ariyawatkul T, Sangvichien S. Anatomy of greater palatine foramen and canal and pterygopalatine fossa in Thais: considerations for maxillary nerve block. *Surg Radiol Anat* 2005; 27:511-516.
- Strandring S, Ellis H, Healy JC, Johnson D, Williams A, Collins P, Wigley C. Gray's anatomy. 40th ed. Edinburgh: *Elsevier Churchill Livingstone*; 2008; 4:502-503.
- Hassanali J, Mwaniki D. Palatal analysis and osteology of the hard palate of the Kenyan African skulls. *Anat Rec* 1984; 209:273-280.
- Mustafa AG, Tashtoush AA, Alshboul OA, Allouh MZ and Altarif AA. Morphometric Study of the Hard Palate and Its Relevance to Dental and Forensic Sciences. *Hindawi International Journal of Dentistry* 2019; Article ID 1687345: 6 pages
- Gangrade P, Babel H, Saini R, Vyas A. Sexing of skull through the morphometric of hard palate. *Int J Curr Res Rev* 2012; 4:168.

9. Saadia A. Shalaby, Esam M. Eid, Naglaa A.S. Sarg, Amany M.A. Sewilam Morphometric analysis of hard palate in Egyptian skulls. *Benha Medical Journal* 2015; 32:59-72.
10. Anil Kumar, Ajmani ML and Heming T. Morphological and morphometric study of hard palate in Indian population. *International Journal of Biomedical Research* 2016; 7(11):778-784.
11. Sujatha N, Manjunath KY, Balasubramanyam V. Variations of the location of the greater palatine foramina in dry human skulls. *Indian J Dent Res* 2005; 16:99-102.
12. Wang TM, Kuo KJ, Shih C, Ho LL, Liu JC. Assessment of the relative locations of the greater palatine foramen in adult Chinese skulls. *Acta Anat (Basel)* 1988; 132:182-186.
13. D'Souza AS, Mamatha H, Jyothi N. Morphometric analysis of hard palate in south Indian skulls. *Biomed Res* 2013; 23:173-175.
14. Jotania B, Patel S, Patel S, Patel P, Patel S, Patel K. Morphometric analysis of hard palate. *Int J Res Med* 2013; 2:72-75.
15. Erli Sarlita, Roger Soames. Morphology of the Hard Palate: A Study of Dry Skulls and Review of the Literature. *Rev Arg de Anat Clin* 2015; 7(1):34-43.
16. Vinay KV, Beena DN and Vishal K. Morphometric analysis of the greater palatine foramen in south Indian adult skulls. *International Journal of Basic Applied Medical Sciences* 2012; 2(3):5-8.
17. Siddiqui AU, Gandhi KR, Daimi SRH, Saxena S, Trivedi S, Sinha MB, Rathore M. Morphometric assessment of the greater palatine foramen with the adjacent anatomical and marks. *Indian Journal of anatomy* 2013; 2(2):61-65.
18. Sharma N, Varshney R, Ray S. Anatomic and anaesthetic considerations of greater palatine nerve block in Indian population. *Saudi Journal of Medicine and Medical Sciences* 2014; 2(3):197-201.
19. Renu C. The position of greater palatine foramen in the adult human skulls of north Indian origin. *Journal of Surgical Academia* 2013; 3(2):54-57.
20. Anjankar VP, Gupta SD, Nair S, Thaduri N, Trivedi GN, Budhiraja V. Analysis of position of greater palatine foramen in central Indian adult skulls: a consideration for maxillary nerve block. *Indian Journal of Pharmaceutical and Biological Research* 2014; 2(1):51-54.

**Cite this article as:** Sinha I, Poddar R and Basu R. Morphometric analysis of hard palate in eastern Indian population. *Al Ameen J Med Sci* 2021; 14(1):20-25.

This is an open access article distributed under the terms of the Creative Commons Attribution-Non Commercial (CC BY-NC 4.0) License, which allows others to remix, adapt and build upon this work non-commercially, as long as the author is credited and the new creations are licensed under the identical terms.

\*All correspondences to: Dr. Iman Sinha, Assistant Professor, Department of Anatomy, Institute of Post Graduate Medical Education and Research, 244, A.J.C Bose Road, Kolkata-700020, West Bengal, India. E-mail: isimansinha@gmail.com