

Totally extra peritoneal inguinal hernia repair

Ashok M. Dhonde^{1*} and Sajid A. Mudhol²

¹Laparoscopic Surgeon, Dhonde Hospital, Central Plaza, Ambedkar Road, Near Blood Bank, Sangli, Maharashtra, India and ²Department of General Surgery, Al Ameen Medical College & Hospital, Athani Road, Vijayapur-586108 Karnataka, India

Introduction

In recent years operative laparoscopy in general surgery has emerged as a viable alternative to traditional open techniques. Cholecystectomy, appendectomy and hernia repair are now routinely performed laparoscopically, with the advantages of less postoperative pain and reduced hospitalization and recuperation periods [1]. Correction of inguinal hernias is one of the most common surgical procedures [2].

In the early 1990s, a variety of trans-abdominal laparoscopic approaches were reported, with the trans-abdominal preperitoneal (TAPP) approach being the most common [3]. In 1993 the laparoscopic total extra peritoneal (TEP) approach was reported by Mckernan. The TEP approach allows for mesh placement within the preperitoneal space, without entering the abdominal cavity [1]. TEP is the current preferred endoscopic mesh techniques in most centers around the world [4].

Here by discussing the important steps of TEP:

Position of patient: Patient lies supine with both arms tucked by side of body, 15 degree head down position with foleys catheter in place. Surgeon stands to the side opposite of the hernia where as endo vision trolley is placed to the same side of hernia and camera surgeon stands behind Surgeon (fig-1).

Ports: All ports in midline. Sub umbilical 10 mm port for telescope and two secondary ports 5 mm each, one in supra pubic and the second in midway between previous ports. The port

position is same for either unilateral or bilateral hernia. The advantage of all midline ports is we have both the instruments working from the beginning of surgery. One should keep 3 mm port or verres needle ready if pneumo peritoneum happens (fig-2).

Fig-1: OT set up

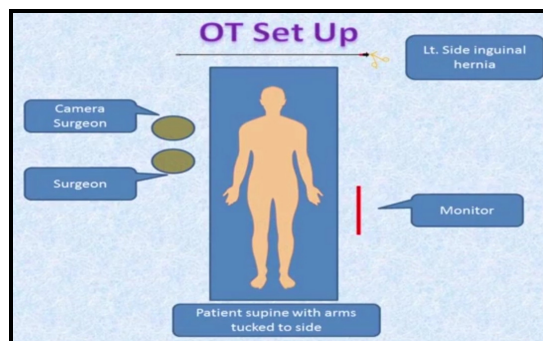
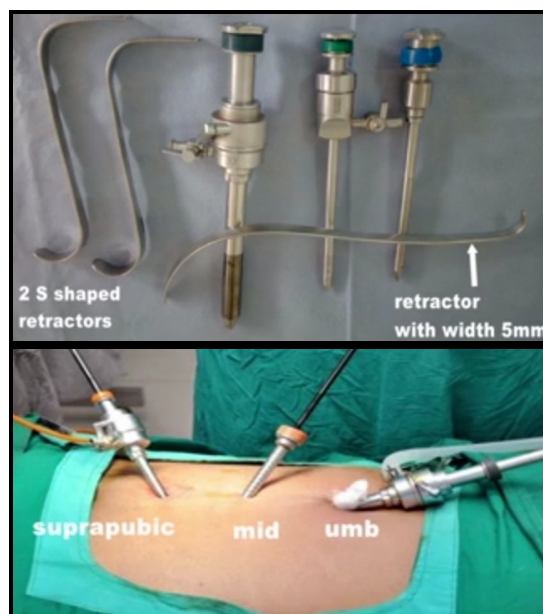


Fig-2: Port and ports sites



Access: In to preperitoneal space and maintaining the space till the end of surgery are the crucial steps for the successful completion of TEP. 10mm transverse sub umbilical incision made to the same side of hernia. Subcutaneous tissue is retracted with help of two S shaped retractors to identify white glistening posterior rectus sheath.

A small incision is given again over rectus sheath and with the help of artery forceps underlying rectus muscle is retracted from midline to the same side to visualize posterior rectus sheath. One should be very careful and avoid bleeding from rectus muscle and avoid opening of peritoneum. Long blade of small S shape retractor is inserted in to pre peritoneal space with this retractor in place a blunt tip 10 mm trocar is introduced tangentially towards direction to symphysis pubis. This port is fixed with suture, the advantage is it will prevent Co2 escape and it will not come out accidentally.

Dissection- Steps

Medial dissection, lateral dissection and dissection of cord structures: To and fro motion of 0 degree telescope is loose areolar plane of fascia transversalis is done to identify pubic bone which is first land mark. The dissection is advanced into retro pubic space i.e Cave of Retzius. One should avoid hitting bone which will cause bleeding from veins of bendavid. Corona Mortis is the vascular anastomotic network located beneath coopers ligament and formed by suprapubic veins, retro pubic veins, branches of inferior IEA and aberrant obturator artery arising from internal iliac artery. Injury to Corona Mortis will cause torrential haaemorrhage.

Both the secondary ports are inserted as mentioned earlier. Both these ports has to enter in preperitoneal space under vision. Dissection is advanced to opposite side of midline .With blunt grasper and scissors one should move laterally to identify coopers ligament. Direct sac will come before the identification of coopers. Direct sac is separated gently from thinned out transversalis fascia. Not to ligate direct sac as it may contain sliding component of hernia.

The pseudosac is pulled inside and tacked above the pubic bone. It prevents bulge in inguinal area post operatively which may be reason of

dissatisfaction for the patient. The inferior epigastric artery [IEA] is identified laterally. The plane of cleavage is opened underneath IEA to enter into Space of Bogros laterally. Laterally our dissection is advanced to define triangle of pain. Laterally we need to go 2 cm above and lateral to anterior superior iliac spine.

One should preserve fibrofatty fascia over ileo-psoas complex. Genital branch of genitofemoral nerve, femoral nerve and lateral cutaneous nerve of thigh are located over ileopsoas complex. IEA should remain undersurface of rectus muscle. One should avoid dissection in between IEA and rectus muscle, which usually happens in learning curve. Indirect sac is pulled medially and cord structures area gently separated laterally.

Testicular vessels will go first and later vas deferens will be seen and separated from peritoneum. Avoid handling the vas as far as possible. Triangle of doom is defined which is bounded medially by vas laterally by testicular vessels and base is formed by peritoneal fold. Our lower limits of dissections is where the vas turns medially. Complete sac should not be reduced, ligated and leave the distal part as it is. Always rule femoral and obturator hernia. Keep holding the peritoneum at different places so chances of opening the peritoneum are minimized.

Cautious use of energy source and avoid bleeding are the key elements to have successful outcome. Wide area of dissection across the midline medially, laterally to ASIS, superiorly up to working posts and inferiorly up to obturator area is mandantatory to prevent recurrence. For bilateral hernia right sided dissection should be done first and later left sided is continued especially in right handed surgeons.

Mesh Preparation: Always change gloves while handling the mesh. Strict asepsis and good large size mesh is mandatory to avoid complications. 12 x 15 cm polypropelene mesh is folded in its half and stay suture is placed at its both ends. The mesh is introduced through 10 mm port. The ridge of mesh will correspond to ileopubic tract. The

lower half of mesh is adjusted first over retropubic space, obturator area and laterally over ileopsoas complex. Two point fixation one over coopers ligament and the other above the pubic bone and not on the bone. Avoid lateral fixation below the ileopubic tract.

The mesh is unfolded like a banana leaf so that it will cover whole of the myopectenial orifice. Avoid crumpling and folding of mesh at its corners to prevent recurrence. CO2 is deflated so that mesh will get sandwiched between cord structures and peritoneum.

Profound knowledge of endoscopic groin anatomy and safe preperitoneal access is key. Training is crucial for the beginners. Good team and advanced Endo vision System will make life easy of the Surgeon

SGRH Recommendations

Beginner:

- ASA gr1
- Low BMI
- [R] sided direct hernia
- No previous surgeries
- No associated co-morbidities
- Uncomplicated
- Umbilicus pubic symphysis length >15 cm

When not to do:

- Unfit patient
- Incarcerated hernia
- Active inflammatory process
- Previous LN irradiation
- Very large scrotal hernia
- Morbidly obese patient

References

1. Mckernal JB, Laws HL. Laparoscopic repair of inguinal hernias using atotally extraperitoneal prosthetic approach. *Surg Endosc.* 1993; 7:26-28.
2. Kingsnorth A, LeBlanc K. Hernias: inguinal and incisional. *Lancet*, 2003; 362:1561-1571.
3. Wake BL, McCormack K, Fraser C. Transabdominal pre-peritoneal (TAPP) vs totally extra peritoneal (TEP) laparoscopic techniques for inguinal hernia repair. *Cochrane Database Syst Rev*, 2005; 1:CD004703.
4. Neumayer L, Giobbie-Hurder A, Jonasson O, Fitzgibbons R Jr, Dunlop D, Gibbs J et al. Open mesh versus laparoscopic mesh repair of inguinal hernia. *N Engl J Med*, 2004; 350:1819-1827.

Cite this article as: Dhonde AM, Mudhol SA. Totally extra peritoneal inguinal hernia repair. *Al Ameen J Med Sci* 2018; 11(3):199-201.

***About the author:** Dr. Ashok M. Dhonde is one of the International Laparoscopic faculty and Pioneer in Laparoscopic Appendectomy, Cholecystectomy and Hernia Repair at Dhonde Hospital, Central Plaza, Ambedkar Road, Near Blood Bank, Sangli, Maharashtra, India. He can be accessible by E-mail: ashokdhonde@yahoo.co.in