

Optic disc and retinal vessel changes in children with surgically treated hydrocephalus: a cross-sectional study

B.K. Bhagyajothi¹, Santosh Kurbet², Tanmay Gupta^{1*}, Arvind L. Tenagi¹,
Rekha Mudhol¹, K.S. Smitha¹ and Nagbhusan Chougule¹

¹Department of Ophthalmology, Jawaharlal Nehru Medical College, KAHER University, Nehru Nagar, Belagavi, Karnataka, India and ²Department of Paediatric Surgery, KLES Dr Prabhakar Kore Hospital and Medical Research Centre, Nehru Nagar, Belagavi, Karnataka, India

Received: 03rd June 2021; Accepted: 28th April 2022; Published: 01st July 2022

Abstract: *AIM:* To study the optic disc and retinal vessel morphology using both indirect ophthalmoscopy and optical coherence tomography in children with surgically treated hydrocephalus. *Methods:* A cross-sectional study was performed with 50 children of surgically treated hydrocephalus as cases and compared them with 50 age matched controls. All children were examined by indirect ophthalmoscopy and optical coherence tomography for the evaluation of optic disc and retinal vessel changes. *Results:* Optic atrophy was found in six out of the fifty children (12%) tested. In comparison with the reference group, median optic disc area was significantly smaller ($p < 0.0001$) in children with hydrocephalus. There was not much difference in cup area, but the rim area was smaller ($p < 0.0001$) in children with hydrocephalus. On indirect ophthalmoscopy children with hydrocephalus had optic atrophy and abnormal retinal vascular pattern. *Conclusion:* Children with surgically treated hydrocephalus were found to have subnormal optic disc and neuro-retinal rim areas with abnormal vascular pattern. The importance of diagnosis of these optic disc and retinal vessel changes in children with surgically treated hydrocephalus by OCT imaging and follow up at regular intervals to look for any additional changes can help us to prevent further damage to the optic nerve.

Keywords: Hydrocephalus, Disc area, Rim area, Cup area, Optical coherence tomography.

Introduction

Hydrocephalus is a condition characterised by increased ventricular size due to increased production or reduced absorption of cerebrospinal fluid [1]. Systemic symptoms such as nausea, vomiting, headache, fatigue, irritability and increased head circumference are helpful to diagnose hydrocephalus [2]. Medical and surgical management are the two treatment options available to restore the intracranial pressure to optimum levels [3]. Both anterior and posterior visual pathways may be affected in children with hydrocephalus resulting in mild to marked loss in visual acuity [1]. The incidence of hydrocephalus during the first year of life is around 1 in 1000 [4].

Ophthalmological manifestations in children with hydrocephalus include reduced vision, double vision, grey-outs, misaligned eyes and visual field defects [4-5]. Papilledema is one of the most

important signs of hydrocephalus; if undetected, it can lead to irreversible damage such as optic atrophy [2]. However in infants and young children papilledema is rare or absent probably due to the open fontanelle permitting the head to enlarge in response to an increased intracranial pressure. It was reported that the hydrocephalus might also cause cognitive visual problems such as decreased depth perception, impaired recognition, impaired motion perception and simultaneous perception [4]. Hence, every individual either child or adult diagnosed with hydrocephalus must undergo baseline ophthalmic evaluation.

Previous research has reported that the hydrocephalus affects the neural tissue resulting in less than normal optic disc and rim areas and also an abnormal vascular pattern, indicating a pre/perinatal influence on the development of neural and vascular tissues

in children [1]. The OCT provides an assessment of the optic nerve head by passing a near -infrared illumination (840 nm) beam into the eye and studying its reflectivity patterns by computer-assisted software [6]). Moreover, in India, no population based morphometric study has been performed on the ocular fundus findings in children with surgically treated hydrocephalus. The present study was therefore intended to detect and quantify optic disc and retinal vessel changes in children who have received surgical treatment for hydrocephalus by using Optical Coherence Tomography.

Material and Methods

Study design and setting: This cross-sectional study was conducted from September 2018 to August 2019 at the Department of Ophthalmology of a Tertiary Care Hospital and Research Centre in Belagavi, after obtaining the ethical clearance from the Institutional Review Board. The study protocol adhered to the tenets of the Declaration of Helsinki and all the parents/guardians of the 50 children included in the study group and 50 children in reference group were briefed regarding the study in detail and informed written consent was documented.

Study population: Children who were referred to the ophthalmology OPD in the age group of 1-14 years, with head circumference > 2 standard deviation score (SDS) greater than body length SDS, enlarged ventricles present at birth, or developed during the first year of life who underwent surgical intervention were included in the study. Children who did not fit the above-mentioned criteria, did not survive during or post-surgery or whose parents/ guardian were unwilling to participate were excluded from the study.

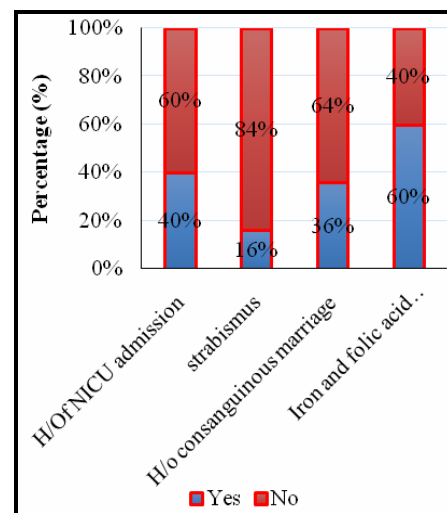
Sample size: Sample size was calculated using G* Power software version 3.1.9.7. Sign test procedure was used for sample size calculation. We assume the effect size as 0.2 and with 80% power, 5% level of significance, minimum samples required for the study was 49 subjects.

Reference group: 50 healthy Indian children between the age group of 1-14 years, who presented to the ophthalmology OPD for routine ophthalmic evaluation were constituted as a reference group for the evaluation of ocular

fundus morphology by optical coherence tomography.

Study Procedure: All the consecutive surgically treated hydrocephalus children who came for follow up were included in the study by consecutive sampling technique. Detailed history regarding demographic data, clinical and family history of the children was recorded. Maternal history including date of last menstrual cycle, number of antenatal visits, gestational age, the mode of delivery, iron and folic acid supplementation was also recorded. Neonatal characteristics such as birth weight, head circumference, history of NICU admission and duration of hospital stay were noted by retrospective review of medical files (fig-1)

Fig-1: Response for maternal and neonatal characteristics



All the children underwent thorough ocular examination including anterior and posterior segment evaluation. Optic disc and retinal vessel evaluation was done by indirect ophthalmoscopy. All the children also underwent optic disc evaluation with the Optical Coherence Tomography (TOPCON) using the 3D disc mode in glaucoma protocol in standard steps [6]. Optic disc area, cup area, rim area, horizontal and vertical disc diameter were recorded. It was difficult to record OCT in very young children in whom we used the head band attached to the head rest to steady the head and parents were allowed to be near the children which increased their comfort and confidence to cooperate for OCT (fig-2 to 4).

Fig-2: Comparison of optic disc area between groups.

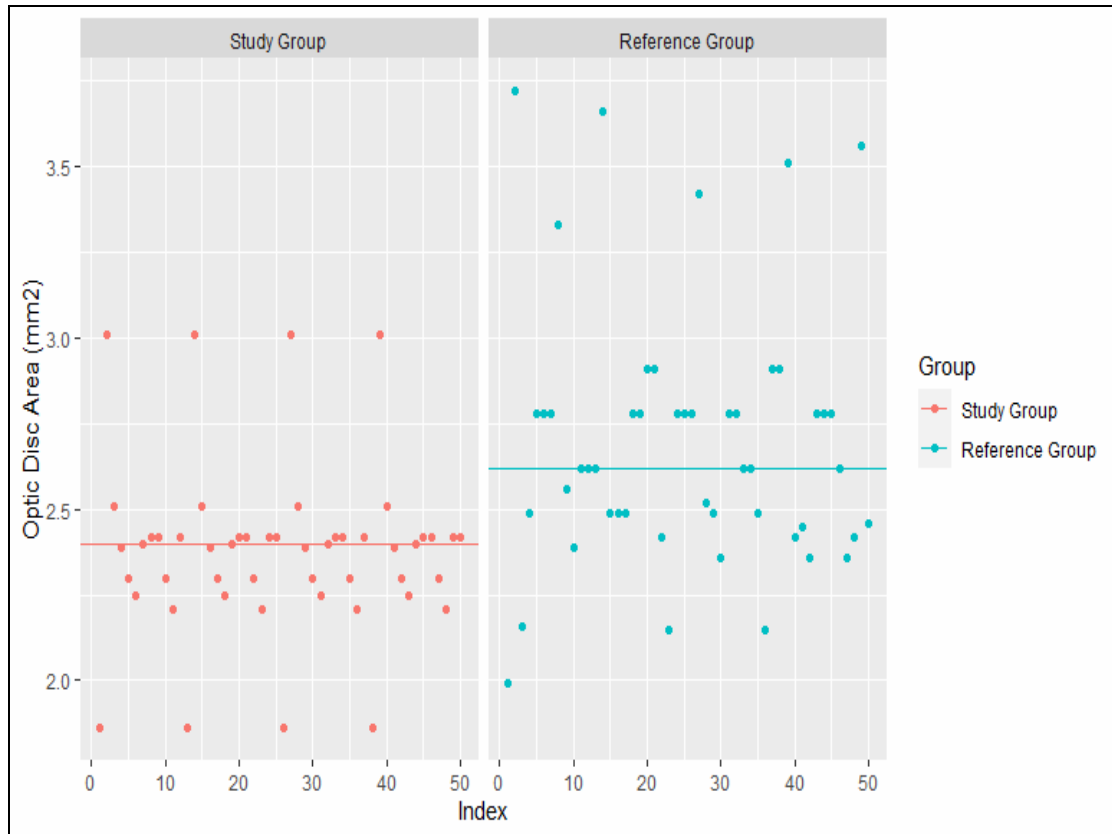


Fig-3: Comparison of rim area between groups.

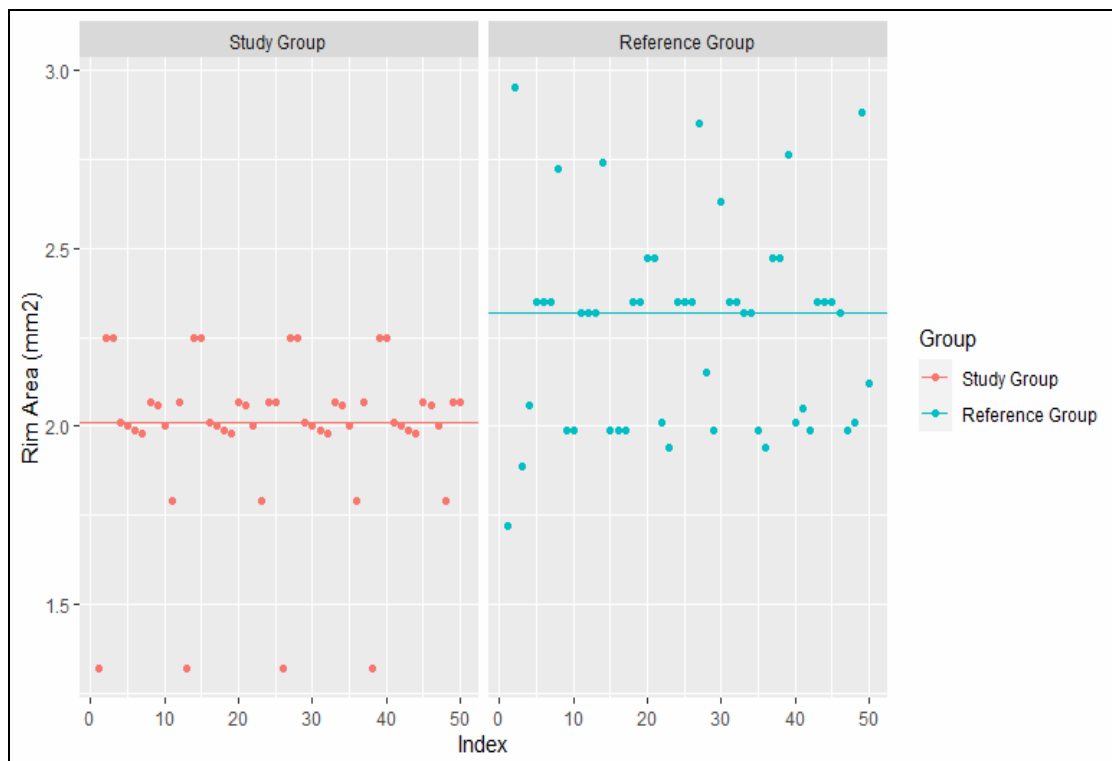
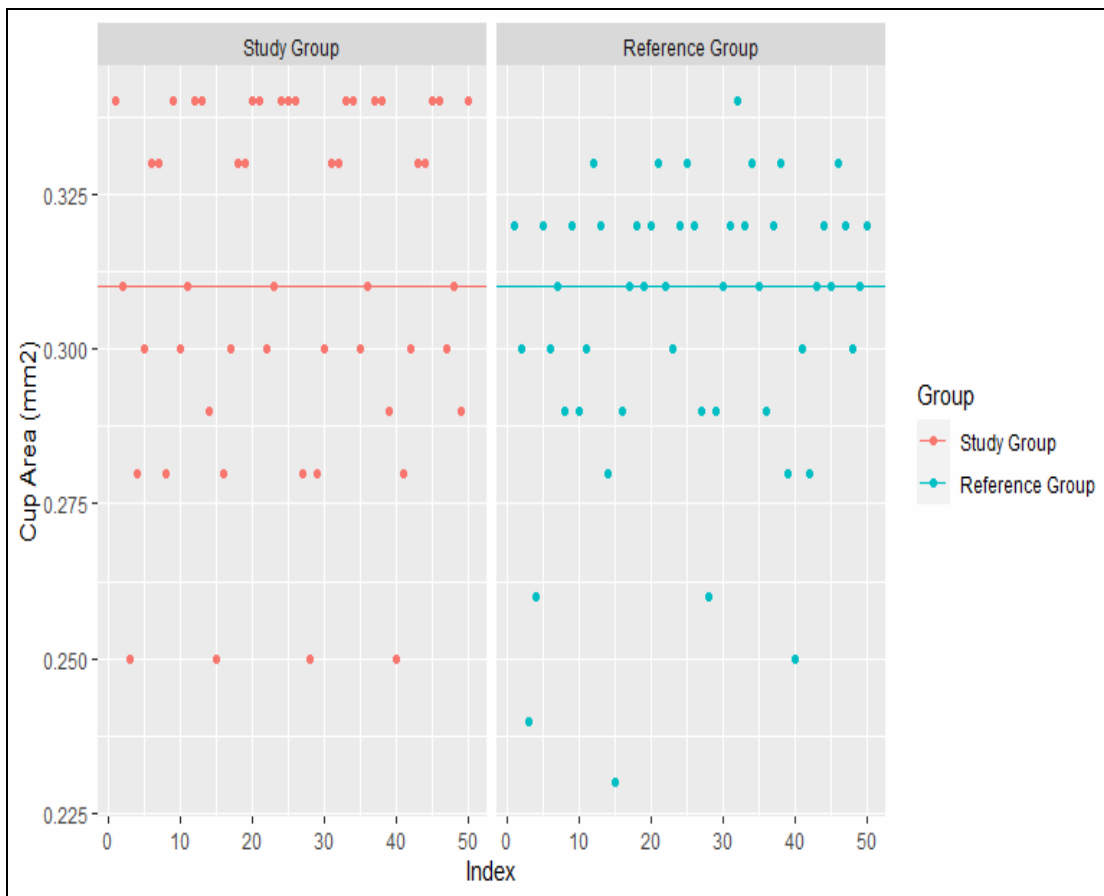


Fig-4: Comparison of cup area between groups.



Statistical Analysis: Data is analysed using statistical software *R version 3.5.1* and Microsoft Excel. Continuous variables are given in the form of mean ± SD/Median (Range). Categorical variables represented using frequency (percentage). Sign test used to compare the median values of different parameters of study group with reference group values. P-value less than or equal to 0.05 indicates statistical significance.

Results

Demographic data: The study population consisted of 50 children, 16 boys and 34 girls of median age 4 [1.5, 14] (in years). Strabismus was noted in eight out of fifty children (16%) out of which six had exotropia and two had esotropia.

On retrospective review of the medical files, the mean gestational age at birth was 36.04 weeks

with a range of 30 to 39 weeks and the mean birth weight was 2.19 kg with a range between 1 to 3 kg in the study group. 20(40%) children in the study group had history of NICU admission (Table 1).

| Parameters | Mean ± SD | Median [Range] |
|----------------------------|--------------|----------------|
| Age (in years) | 5.32 ± 4.09 | 4 [1.5,14] |
| Birth weight (in kg) | 2.19 ± 0.66 | 2.5 [1,3] |
| Gestational Age (in weeks) | 36.04 ± 3.17 | 37 [30,39] |

Optic-nerve morphology: Optic disc variables for children with hydrocephalus and reference group are shown in Table 2.

| Par Parameters | Study Group (median) | Reference Group (median) | p-value |
|------------------------------------|-----------------------------|---------------------------------|----------------|
| Optic disc Area (mm ²) | 2.39 [1.86,3.04] | 2.42 | 0.0012 |
| Cup Area (mm ²) | 0.31 [0.25,0.34] | 0.31 | 0.766 |
| Rim Area (mm ²) | 2.01[1.32,2.25] | 2.07 | 0.0002 |
| Horizontal Disc Diameter (mm) | 1.42 [0.74,2.11] | 1.66 | 0.0002 |
| Vertical Disc Diameter (mm) | 2.01 [1.80,2.98] | 2.04 | 0.0114 |

Using sign test, the study gathered that the children with hydrocephalus had a smaller median optic disc area of 2.39mm² than the reference group of healthy children, 2.42mm² (p<0.0012). Neuroretinal rim area was 2.01 mm² in the study group which was smaller compared to 2.07mm² of the reference group. Median of horizontal D.D. and vertical D.D. was 1.42mm and 2.10mm in the study group which was significantly different from 1.66 mm and 2.04 mm in reference group respectively. It was observed that, there was no significant difference in the median value cup area of study group when compared with reference group (Table 2).

On indirect ophthalmoscopy six out of fifty children (12%) showed optic atrophy and abnormal retinal vascular pattern like straighter retinal arteries and central vessel branching points in the study group as compared to reference group.

Discussion

Children with hydrocephalus were found to have abnormal optic disc morphology in comparison with the reference group, illustrated by smaller optic disc and rim areas with abnormal retinal vascular pattern. Neuroretinal rim area had a significant difference between hydrocephalus children and the reference group. These findings were consistent with a study by Anderson et al [1]. This study did not show a significant difference in the vertical and horizontal disc diameter when compared to the reference group.

The smaller disc areas may reflect a reduced number of optic nerve axons, as indicated in other clinical studies [7] that the size of the disc is related to the number of axons. So we can speculate that the reduced optic disc and rim areas in children with hydrocephalus could be of a prenatal origin [1].

Variation in optic disc morphology has been suggested to be caused by a lot of other factors such as secondary degeneration of ganglion cells and their fibres (retrograde, transsynaptic or non-transsynaptic), defective trophic mechanisms or deficient myelination [1]. A study by McLoone et al showed no significant association between disc morphology and the timing of the cerebral insult [8]. Also in a similar study in the past, no correlation had been found between aetiology of hydrocephalus and ocular fundus variables [1]. The study results correlated with the results of the studies mentioned above.

Raised intracranial pressure causes compressive optic neuropathy at the junction of lamina cribrosa and optic nerve sheath leading to blockage of the axoplasmic flow in retinal ganglion cell axons causing their loss resulting in pale optic disc and optic atrophy. Histologically optic nerve head is characterised by a reduction in both number of axons and optic nerve diameter [1].

In the present study six out of fifty children (12%) had optic atrophy. In another study done by Andersson et al showed optic atrophy in 14% of children with hydrocephalus which was similar to the findings of our study [1]. Similar incidence of optic atrophy of 17% was found in the study done by Gaston [9].

In another study done by Akinsola F B et al optic atrophy was found in 30% of children with hydrocephalus which was slightly higher compared to our study [10]. 20% of children with hydrocephalus had optic disc abnormalities in another study done by S Akca Bayar et al [11]. Optic disc changes in the form of optic atrophy was noted in study done on large series of 200 consecutive cases

by S Ghose et al [12]. The hydrocephalus was found to be third most frequently observed etiology in children < 16 years of age with unilateral or bilateral optic atrophy [13].

A non-specific response to the neurological insult was found in the form of strabismus, eight out of fifty children (16%) had strabismus, among which six had exotropia and two had esotropia. In study done by S Akca Bayar et al, 51.2% of children showed strabismus [11] which was similar to study done by S Andersson [1] where strabismus was noticed in 72% of children. Another study by Ozgul Altintas et al also found that 40% of children were having strabismus in his study [14].

In another study strabismus was found in 68.9% of children with hydrocephalus treated surgically before 1 year of age [15] which was similar to another study by Andersson et al where strabismus was noted in 69% of children with surgically treated hydrocephalus [4]. All these studies showed a very high prevalence of strabismus in children with hydrocephalus who underwent shunt surgery which did not correlate with the findings of our present study. None of the children with hydrocephalus who presented to the OPD had nystagmus or epilepsy.

Conclusion

Hydrocephalus in children is known to affect neural tissues resulting in an abnormal disc morphology, smaller disc area, rim area and abnormal vascular pattern as observed in this study. These abnormal findings indicate pre or perinatal influence on neural and vascular tissue development in children with hydrocephalus. Hydrocephalus has also been associated with optic atrophy and strabismus which was noted in our study. The importance of diagnosis of these optic disc and retinal vessel changes in children with surgically treated hydrocephalus by OCT imaging and follow up at regular intervals to look for any additional changes can help us to prevent further damage to the optic nerve.

The OCT imaging in these children will help us to correctly assess the changes in optic disc morphology more accurately than indirect ophthalmoscopy. The OCT is useful tool to assess the optic disc changes in children with surgically treated hydrocephalus. The ophthalmologist also has an established role along with paediatric neurologist and paediatric surgeon in the long term management of children with hydrocephalus if risk of blindness is not to be added to their physical disabilities.

Financial Support and sponsorship: Nil

Conflicts of interest: There are no conflicts of interest.

References

1. Andersson S, Hellström A. Abnormal optic disc and retinal vessels in children with surgically treated hydrocephalus. *British Journal of Ophthalmology*, 2009; 93:526-530.
2. Lee HJ, Phi JH, Kim S-K, Wang K-C, Kim S-J. Papilledema in children with hydrocephalus: incidence and associated factors. *Journal of Neurosurgery: Pediatrics*, 2017; 19:627-631.
3. Singhal V, Prabhakar H. Hydrocephalus. Complications in Neuroanesthesia. *Elsevier*, 2016; 21-27.
4. Andersson S, Persson EK, Aring E, Lindquist B, Dutton GN, Hellström A. Vision in children with hydrocephalus. *Developmental medicine and child neurology*, 2006; 48:836-841.
5. Eye Problems Associated with Hydrocephalus San Francisco: *Hydrocephalus Association*; [Cited on 04-09-2019] Available from: https://www.hydroassoc.org/docs/FactSheet_Eye_Problems.pdf
6. Shaun Dacosta et al. Optic disc topography of normal Indian eyes: An assessment using optical coherence tomography. *Indian J Ophthalmol*, 2008; 56:99-102.
7. Jonas JB, Schmidt AM, Müller-Bergh JA, Schlötzer-Schrehardt UM, Naumann GO. Human optic nerve fiber count and optic disc size. *Invest Ophthalmol Vis Sci*. 1992; 33(6):2012-2018.
8. McLoone E et al. Retcam image analysis of optic disc morphology In premature infants and its relation to ischaemic brain injury. *Br J ophthalmol*, 2006; 90:465-471.
9. Gaston H. Ophthalmic complications of spina bifida and hydrocephalus. *Eye (Lond)*. 1991; 5 (Pt 3):279-290.
10. Akinsola FB, Yusuf GF, Bankole OB, Kanu OO, Onakoya AO, Aribaba OT. Hydrocephalus and the eyes: a teaching hospital experience. *Nig Q J Hosp Med*. 2011; 21(4):252-254.

11. Akca Bayar S, Kayaarasi Ozturker Z, Oto S, Gokmen O, Sezer T. Pattern of oculomotor and visual function in children with hydrocephalus. *J Fr Ophthalmol*, 2021; 44(9):1340-1348.
12. Ghose S. Optic nerve changes in hydrocephalus. *Trans Ophthalmol Soc UK*. 1983; 103(Pt 2):217-220.
13. Chinta S, Wallang BS, Sachdeva V, Gupta A, Patil-Chhablani P, Kekunnaya R. Etiology and clinical profile of childhood optic nerve atrophy at a tertiary eye care center in South India. *Indian J Ophthalmol*, 2014; 62(10):1003-1007.
14. Altintas O, Etus V, Etus H, Ceylan S, Caglar Y. Risk of strabismus and amblyopia in children with hydrocephalus. *Graefes Arch Clin Exp Ophthalmol*, 2005; 243(12):1213-1217.
15. Aring E, Andersson S, Hård AL, Hellström A, Persson EK, Uvebrant P, Ygge J, Hellström A. Strabismus,

binocular functions and ocular motility in children with hydrocephalus. *Strabismus*, 2007; 15(2):79-88.

Cite this article as: Bhagyajyothi BK, Kurbet S, Gupta T, Tenagi AL, Mudhol R, Smitha KS and Chougule N. Optic disc and retinal vessel changes in children with surgically treated hydrocephalus: a cross-sectional study. *Al Ameen J Med Sci* 2022; 15(3): 242-248.

This is an open access article distributed under the terms of the Creative Commons Attribution-Non Commercial (CC BY-NC 4.0) License, which allows others to remix, adapt and build upon this work non-commercially, as long as the author is credited and the new creations are licensed under the identical terms.

*All correspondences to: Dr. Tanmay Gupta, Post Graduate Resident, Department of Ophthalmology, Jawaharlal Nehru Medical College, KAHAR University, Nehru Nagar, Belagavi, Karnataka, India. E-mail: drtanmaygupta@gmail.com