

## A study of preoperative, intraoperative and postoperative complications of pseudoexfoliation syndrome in Indian eyes undergoing cataract surgery

Vybhavi P. Kaushik, Madhu A. Gannur, Z.A. Golewale, Anand G. Gannur\* and Ayesha Batool

Department of Ophthalmology, AI Ameen Medical College and Hospital, Athani Road, Vijayapur-586108 Karnataka, India

Received: 15<sup>th</sup> July 2022; Accepted: 25<sup>th</sup> December 2022; Published: 01<sup>st</sup> July 2023

**Abstract:** *Objectives:* To study the clinical profile and complications encountered in the management of cataract patients with pseudo exfoliation syndrome (PXF). *Method:* A cross sectional hospital based study was done on 50 eyes of 50 patients in a tertiary care, Bijapur from January 2022 to May 2022. All these patients were above fifty and were diagnosed as cataract associated with PXF. Patients with previous history of trauma and ocular surgery, true exfoliation and patients with systemic comorbidities like uncontrolled DM, CVD, stroke, etc were excluded from the study. All patients underwent manual SICS with intraocular lens implantation. Preoperative, intraoperative and postoperative complications were studied. Patients were reviewed upto 6 weeks post-op. *Results:* A total of 50 eyes of 50 patients diagnosed as cataract with pseudo exfoliation underwent small incision cataract surgery. Preoperatively 6(12%) cases had zonular weakness, 1(2%) case had glaucoma and 8(16%) cases had insufficient mydriasis. Intraoperatively-5(10%) cases had zonular dialysis, 3(6%) cases had Posterior capsular rent, 4(8%) had vitreous loss and 2(4%) sphincterotomies. Postoperatively-6(12%) cases had pupillary fibrin membrane, 2(4%) cases of iritis. *Conclusion:* Cataract surgery in patients with pseudoexfoliation syndrome has higher incidence of preoperative, intraoperative and postoperative complications. Insufficient mydriasis being the most common preoperative complication, zonular dialysis the most common intraoperative and pupillary fibrin membrane the most common post operative complication. A complete preoperative workup helps reduce intraoperative complications and maximizes the postoperative results.

**Keywords:** Pseudoexfoliation, Insufficient Mydriasis, Glaucoma, Zonular Dislocation.

### Introduction

Pseudoexfoliation syndrome (PXF) is an age related condition characterized by the deposition of fibrillar material in various anatomic locations [1] typically in structures of the anterior segment including the lens epithelium, lens capsule, iris pigment epithelium, iris stroma and iris blood vessels, pupillary margin, zonular fibres, ciliary processes trabecular meshwork and endothelium and systemic tissues [2].

Recent genetic studies indicate the lysyl oxidase like (LOXL1) gene responsible for enzyme that synthesizes and maintains elastic fibrosis a major. The LOXL1 gene product is responsible for catalysing the formation of elastin fibres [3]. Patients with this syndrome respond poorly to

pharmacological dilators, other complications associated with cataract surgery in PXF can occur from poor pupillary dilatation, zonular weakness leading to intraoperative or postoperative lens dislocation and vitreous loss, postoperative intraocular pressure (IOP) spikes potentiating glaucomatous damage, capsular phimosis, prolonged inflammation and postoperative corneal decompensation [4-5]. Histochemical studies have shown that zonular fibres are affected and thus weakened by these deposits, thus PXF increases the risk of capsular rupture and disinsertion in eyes [6].

Other risk factors for developing PXF include age, family history, female gender and even geographic areas of residence including higher latitudes [7]. A prevalence of 3.8% is reported

in rural South Indian population [8]. Therefore a proper preoperative workup of all cases of PXF with detailed examination on slit lamp both before and after pupillary dilatation is mandatory. Thus a thorough preoperative workup helps us choose appropriate surgical procedures

**Material and Methods**

This study is a hospital based cross sectional study done in 50 patients diagnosed with both cataract and PXF. Diagnosis of PXF was done based on white grey material on the anterior lens capsule and pupillary area as seen on slit lamp. Patients aged more than 50 and diagnosed with PXF and cataract were included in our study. Patients less than 50 years with previous history of trauma, complicated cataract, ocular surgery, true exfoliation and presence of any systemic complications like uncontrolled diabetes, cardiovascular diseases or stroke were excluded.

All patients underwent complete ophthalmic examinations which included visual acuity testing using Snellen’s chart, Goldmann’s applanation tonometry for intraocular pressure. Detailed slit lamp evaluation as mentioned before and after dilatation to assess relevant preoperative observations including PXF deposition, type, and grade of the cataract, presence of phacodonesis or zonulolysis. Angle evaluation done with the help of goldmanns four mirror gonioscope and graded by Shaffer’s grading system. Anterior chamber depth and axial length by A scan biometry. A detailed fundus examination was conducted. Mandatory B scan and necessary blood investigations like complete blood count, HIV, HbsAg, random blood sugar, urine routine were tested.

All observations and demographic data for each eye were carefully recorded using excel sheet. All patients underwent manual SICS. Pre operative pupillary diameter after dilatation was graded as follows-poor (2-4 mm), moderate (5-6mm) and good (7-9mm). This grading was similar to the one used by Pranathi K et al in their study[9].

*Surgical procedure:* Anesthesia was given by means of peribulbar block using 5ml lignocaine and 3ml bupivacaine. Bridle suture was put. Conjunctival peritomy was done with conjunctival scissors. Scleral incision was made with Bard Parker knife with 15 number blade

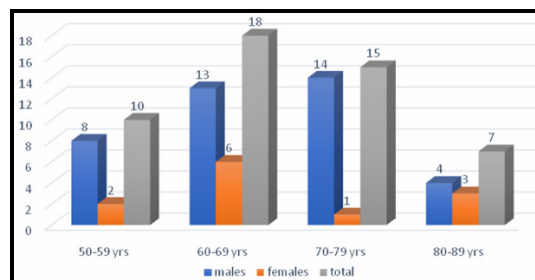
super temporally and sclerocorneal tunnel was constructed with the crescent blade. Continuous curvilinear capsulorrhexis aimed at 5-5.5mm was done using the needle cystitome and completed with the same. A thorough hydro dissection was done to separate cortex from nucleus. Nucleus was delivered by visco expression. Irrigation and aspiration was done with Simco’s two way irrigation and aspiration canula. Rigid, single piece, biconvex, PMMA PCIOL with optical diameter of 5.25 mm was implanted in the bag.

Patients were followed up till 1 week postoperative period. Patients were given postoperative steroid plus antibiotic combination along with tropicacyl eyedrops. Systemic antibiotics and NSAIDS were also given.

**Results**

The patients demographic details were taken initially. A total of 50 people underwent examination. Out the 50 people maximum (72 %) were males and the remaining 28% were females [fig 1].

**Fig-1:** Age and gender distribution



The prevalence of PXF was found to be more in the male population according to our study. Amongst the 50, maximum belonged to the age group of 60-69 years which is 18 people. Out of them 13 were males and 6 were females [Table-1].

It is seen that mixed cataracts are more common in PXF in our study. Out of which nuclear cataract seems to be more commonly seen in PXF patients (76%) followed by posterior subcapsular cataract (60%) and cortical cataract (30%).

Preoperative visual acuity, 10 patients had vision from 6/60 to 6/12(20%), 30 patients (60%) had counting fingers, 10 had vision from 6/60-6/12, 7 of them had a vision of hand movements and 3 patients had vision of perception of light. The mean anterior chamber depth was 3.394mm, mean axial length was 22.7138 and the mean preoperative IOP was 13.88mm Hg.

A total of 50 patients diagnosed with pseudoexfoliation and cataract underwent a thorough pre operative evaluation and the following complications were observed in some of the individuals [Table-1]. The most common preoperative complication was insufficient mydriasis which included 8 patients. Stretch pupiloplasty was done for 4 patients and iris hooks were used for 2 patients. For the remaining two patients sphincterotomy was done. One patient was diagnosed with glaucoma with 34 mmHg which was controlled medically and then operated. Zonular weakness or phacodonesis was found in 6 patients.

Clinical Features	Number	% age
Zonular weakness/phacodonesis	6	12%
Glaucoma	1	2%
Insufficient mydriasis	8	16%

All the 50 patients underwent manual SICS. The most common intraoperative complication [Table-2] was zonular dislocation which was seen in 10% of the patients. Out of the 5, three of them previously had severe weak zonules for which capsular tension ring was put followed by PCIOL. For the other two cases Iris claw lens was used.3 patients had capsular rent for which iris claw intraocular lens was put. Vitreous loss was seen in 4 patients. Sphincterotomy was done in 2 patients due to poor mydriasis.

Intraoperative complication	Number	% age
Zonular dislocation	5	10%
Posterior capsule rent	3	6%
Vitreous loss	4	8%
sphincterotomy	2	4%

Mean postoperative IOP was 14mm Hg .Most common postoperative complication was pupillary fibrin membrane observed on day one postop which included 6 patients (12%), aqueous cells and flare were seen in 2 patients (4%). And iris synechiae was seen in 2 patients (4%) (Table-3).

Postoperative complication	Number	% age
Increased intraocular pressure	Nil	-
Pupillary fibrin membrane	6	12%
Aqueous cells/flare	2	4%
Iris synechiae	2	4%
IOL decentration	Nil	-
Retained lens matter	Nil	-
Post op hyphema	Nil	-

Post operative visual acuity in 70% of the patients was 6/6-6/12.20% patients had 6/18 - 6/36 vision and 10 % had vision less than 6/60 (Table-4)

Post operative visual acuity	Number	Percentage
6/6-6/12	35	70%
6/18-6/36	10	20%
6/60 or less	5	10%

At the end of one week the postoperative vision remained the same in almost all patients. Pupillary fibrin membrane improved in all patients but was still present. Reduction in aqueous cells and flare was seen.

### Discussion

Lindberg [10] first described PXF in 1917. The syndrome causes a spectrum of intraocular and extraocular manifestations caused by pseudoexfoliative material [11]. The prevalence of PXF increases with rise in the mean age of the general population [12]. In our study the mean age was 70 years and most of the patients belonged to the age group 60-69 years.

An association between PXF and cataract has been observed. Slit lamp evaluation showed that mixed cataract was the predominant in our study. Puska [13] reports a higher prevalence of subcapsular cataracts and several other studies of [12] nuclear sclerosis in eyes with PXF. Our study showed that among the mixed cataracts nuclear sclerosis is more commonly associated with PXF. Honjo [14] et al. reported a mean preoperative IOP of 24.5mm Hg  $\pm$ 4.8 (SD) in eyes with PXF which is significantly higher than the mean in our study which is 13.88mm Hg.

Assia et al report that the zonules in the eyes with PXF are more fragile than those in normal eyes of similar age [15]. The presence of degenerative changes in the zonular fibres in the patients with PXF especially near the ciliary processes as well as the lower stretching capability observed in experimental studies are related to higher incidence of phacodonesis in patients with PXF. In our study 12% of the patients had phacodonesis. Allfaite and coauthors report a significantly higher rate of phacodonesis in eyes with pseudoexfoliation [16]. Shingleton and coauthors found that 60% of the people with zonular weakness confirmed by phacodonesis developed vitreous loss during surgery [5]. Moreno and coauthors found a significantly higher incidence of iridophacodonesis in eyes with PXF having light coloured irides than in those with dark irides. This indicates the possibility of less severe damage in eyes with dark irides [12].

Eyes with PXF are almost always characterized by poor mydriasis. In our study 16% of the patients had insufficient mydriasis i.e between 2-4 mm. In our opinion Sphincterotomies are recommended in these cases. Sector iridectomy or radial iridotomy is not recommended in the cases of insufficient mydriasis as sectioning the innermost part of the sphincter in three places, about 120 degrees apart is sufficient to achieve an acceptable degree of mydriasis. Alternatively. The use of pupil stretching maneuvers/devices is reported to overcome the problems of insufficient mydriasis [17]

SICS was done for all the patients in our study. Cataract surgery by conventional extracapsular cataract extraction (ECCE) in eyes with PXF results in an increased risk and incidence of

complications such as zonular dehiscence, capsule tear/rupture, and vitreous loss [12]. Drosalum [18] and coauthors found a frequency of 9.6% of capsular tear, zonular tear, or vitreous loss in eyes with PXF compared with 3.7% in eye without this syndrome. Scoroli et al report a significantly higher incidence of intraoperative complications in the eyes with PXF than in those without this syndrome [19]. Shingleton and co-authors, the rate of vitreous loss was 4% in the PXF eyes and 0% in the non PXF group. In our study vitreous loss was seen in 8% of the patients [5]

A transient breakdown of aqueous blood barrier occurs during cataract surgery with IOL implantation [20]. In addition the iris vessels are pathological with an increased permeability for protein in eyes with PXF [21]. This may explain the significantly higher flare response in postoperative patients after one week despite uneventful surgery. Drosalum [22] and coauthors also report a significantly higher tendency toward more inflammation in eyes with pseudoexfoliation. However, other studies found the inflammatory reactions after phacoemulsification in eyes with PXF to be within normal limits [23].

The intraoperative trauma of ECCE alters the blood aqueous barrier (BAB) [24]. Iris angiography studies demonstrate the presence of "micro neovascularisation of the iris" with fluorescein leakage in patients with PXF [25]. Allfaite et al [16] observed a statistically significant increase in the formation of pupillary fibrin membranes in eyes with PXF (29% versus 3.2%) which in their opinion was related to previous BAB alterations. An association between this complication and the formation of iris synechiae was also observed. The increased incidence of this fibrinoid reaction after ECCE in patients with PXF has been described by some authors [26]. Traumatic delivery of the nucleus through a poorly dilated pupil has been cited as a significant factor in exaggerated postoperative inflammatory response in eyes with PXF [18].

In a study by Michael Hyams et al [27] univariate and multivariate analysis showed that a longer axial length is a protective factor

against the occurrence of zonular tear during phacoemulsification. In contrast Kuchle [28] and authors report that axial length was shorter in eyes with PXF and complications than in eyes without complications, but the difference was not significant. A recent report evaluated the relative intraoperative risk as a function of anterior chamber depth and presumably greater preoperative zonular laxity, higher rates of intraoperative zonular dialysis vitreous loss or both were found [29].

Several studies report that anterior capsule contraction in PXF and potentially weakened zonule can lead to late lens decentration [30]. Anterior capsular contraction and phimosis are more common in PXF particularly in the presence of smaller capsulorrhexis [31]. A neodymium: YAG (Nd:YAG) laser can be used to correct phimosis by performing radial laser incisions through the circumferential anterior capsular bag releasing the centripetal traction on the anterior

capsule and zonules. PXF is a risk factor for the development of chronic open angle glaucoma [32].

### Conclusion

It can be said that cataract with pseudoexfoliation may propose a challenging scenario during manual SICS. These challenges may be properly handled by a thorough preoperative evaluation to expect certain intraoperative complications and be prepared during the surgery. From our study it can be concluded that most of the complications be it preop, intraop or post op can be managed by a strategic plan of action that differs from patient to patient. Use of affordable and easy surgical accessories like iris claw, capsular tension rings, iris retractors and hooks help us to manage such complications in a better way with acceptable visual outcomes.

**Financial Support and sponsorship:** Nil

**Conflicts of interest:** There are no conflicts of interest.

### References

1. Elhawy E, Kamthan G, Dong CQ, Danias J. Pseudoexfoliation syndrome, a systemic disorder with ocular manifestations. *Hum Genomics*. 2012; 6:22.
2. Schlotzer-Schrehardt U, Naumann GOH. Ocular and systemic pseudoexfoliation syndrome. *Am J Ophthalmol*. 2006; 141:921-937.
3. Kastelan S, Tomic M, Kordic R et al. Cataract surgery in eyes with pseudoexfoliation syndrome. *J Clin Exp Ophthalmol*. 2013; S1:009.
4. Kanthan GL, Mitchell P, Burlutsky G et al. Pseudoexfoliation Syndrome and the long-term incidence of cataract and cataract surgery: The Blue Mountain Eye Study. *Am J Ophthalmol*. 2013; 155:83-88.
5. Shingleton BJ, Heltzer J, O'Donoghue MW. Outcomes of phacomulsification in patients with and without pseudoexfoliation syndrome. *J Cataract Refract Surg*. 2003; 29:1080-1086.
6. Raitta C, Setälä K. Intraocular lens implantation in exfoliation syndrome and capsular glaucoma. *Acta Ophthalmol (Copenh)*. 1986; 64:130-133.
7. Kang JH, Loomis S, Wiggs JL et al. Demographic and geographic features of exfoliation glaucoma in two United States based prospective cohorts. *Ophthalmology* 2012; 119(1):27-35.
8. Arvind H, Raju P, Paul PG, Baskaran M, Ramesh SV, George RJ et al. Pseudoexfoliation in South India. *Br J Ophthalmol*. 2003; 87(11):1321-1323.
9. Pranathi K, Magdum RM, Maheshgauri R, Patel K, Patra S. A study of complications during cataract surgery in patients with pseudoexfoliation syndrome. *J Clin Ophthalmol Res*. 2014; 2:7-11.
10. Lindberg JG. Clinical investigations on depigmentation of the pupillary border and translucency of the iris in cases of senile cataract and in normal eyes in elderly persons. *Acta Ophthalmol Suppl* (1985). 1989; 190:1-96.
11. Schlotzer-Schrehardt, Dorfler SU, Naumann GOH. Corneal endothelial involvement in pseudoexfoliation syndrome. *Arch Ophthalmol*. 1993; 111:666-674.
12. Moreno J, Duch S, Lajara J. Pseudoexfoliation syndrome: clinical factors related to capsular rupture in cataract surgery. *Acta Ophthalmol*. 1993; 71:181-184.
13. Puska P. Lens opacity in unilateral exfoliation syndrome with or without glaucoma. *Acta Ophthalmol*. 1994; 72:290-296.
14. Honjo M, Tanihara H, Inatani M et al. Phacoemulsification, intraocular lens implantation, and trabeculotomy to treat pseudoexfoliation syndrome. *J Cataract Refract Surg*. 1998; 24:781-786.
15. Assia EI, Apple DJ, Morgan RC et al. The relationship between the stretching capability of the anterior capsule and zonules. *Invest Ophthalmol Vis Sci*. 1991; 32:2835-2839.
16. Alfaiate M, Leite E, Mira J, Cunha-Vaz JG. Prevalence and surgical complications of pseudoexfoliation syndrome in Portuguese patients with senile cataract. *J Cataract Refract Surg*. 1996; 22:972-976.

17. Freyler H, Radax U. Pseudoexfoliationssyndrom--ein Risikofaktor der modernen Kataraktchirurgie? [Pseudoexfoliation syndrome--a risk factor in modern cataract surgery?]. *Klin Monbl Augenheilkd*. 1994; 205(5):275-279. German.
18. Drolsum L, Haaskjold E, Davanger M. Pseudoexfoliation syndrome and extracapsular cataract extraction. *Acta Ophthalmol*. 1993; 71:765-776.
19. Scorolli L, Scorolli L, Campos EC et al. Pseudoexfoliation syndrome: a cohort study on intraoperative complications in cataract surgery. *Ophthalmologica*. 1998; 212:278-280.
20. Kaiya T. Observation of blood-aqueous barrier function after posterior chamber intraocular lens implantation. *J Cataract Refract Surg*. 1990; 16:320-324.
21. Spinelli D, de Felice GP, Vigasio F, Coggi G. The iris vessels in the exfoliation syndrome; ultrastructural changes. *Exp Eye Res*. 1985; 41:449-455.
22. Drolsum L, Haaskjold E, Sandvig K. Phacoemulsification in eyes with pseudoexfoliation. *J Cataract Refract Surg*. 1998; 24:787-792.
23. Dosso AA, Bonvin ER, Leuenberger PM. Exfoliation syndrome and phacoemulsification. *J Cataract Refract Surg*. 1997; 23:122-125.
24. Leite E, Mira JB, Mota MC, Cunha-vaz G. Evaluation of quality of cataract surgery. II. Inflammatory response. *Eur J Implant Refract Surg*. 1990; 2:9-13.
25. Goder GJ. Our experiences in planned extracapsular cataract extraction in the exfoliation syndrome. *Acta Ophthalmol Suppl*. 1988; 184:126-128.
26. Brazitikos PO, Roth A. Iris modifications following extracapsular cataract extraction with posterior chamber lens implantation. *J Cataract Refract Surg*. 1991; 17:269-280.
27. Hyams M, Mathalone N, Herskovitz M, Hod Y, Israeli D, Geyer O. Intraoperative complications of phacoemulsification in eyes with and without pseudoexfoliation. *J Cataract Refract Surg*. 2005; 31(5):1002-1005.
28. Kuchle M, Schönherr U, Dieckmann U. Risikofaktoren für Kapselruptur und Glaskörperverlust bei extrakapsulärer Kataraktextraktion. Erlanger Augenblätter-Gruppe [Risk factors for capsular rupture and vitreous loss in extracapsular cataract extraction. The Erlangen Ophthalmology Group]. *Fortschr Ophthalmol*. 1989; 86(5):417-21. German.
29. Kuchle M, Viestenz A, Martus P, Händel A, Jünemann A, Naumann GO. Anterior chamber depth and complications during cataract surgery in eyes with pseudoexfoliation syndrome. *Am J Ophthalmol*. 2000; 129(3):281-285.
30. Davison JA. Capsule contraction syndrome. *J Cataract Refract Surg*. 1993; 19:582-589.
31. Hayashi H, Hayashi K, Nakao F, Hayashi F. Anterior capsule contraction and intraocular lens dislocation in eyes with pseudoexfoliation syndrome. *Br J Ophthalmol*. 1998; 82:1429-1432.
32. Colin J, Le Gall G, Le Jeune B, Cambrai MD. The prevalence of exfoliation syndrome in different areas of France. *Acta Ophthalmol Suppl (1985)*. 1988; 184:86-89.

**Cite this article as:** Vybhavi PK, Gannur AG, Golewale ZA, Gannur MA and Batool A. A study of preoperative, intraoperative and postoperative complications of pseudoexfoliation syndrome in Indian eyes undergoing cataract surgery. *Al Ameen J Med Sci* 2023; 16(3):255-260.

This is an open access article distributed under the terms of the Creative Commons Attribution-Non Commercial (CC BY-NC 4.0) License, which allows others to remix, adapt and build upon this work non-commercially, as long as the author is credited and the new creations are licensed under the identical terms.

\*All correspondences to: Dr. Anand G. Gannur, Professor, Department of Ophthalmology, Al Ameen Medical College and Hospital, Athani Road, Vijayapur-586108 Karnataka, India. E-mail: anandggannur@yahoo.com